

Acidic Electrolysed Water in the Disinfection of the Ocular Surface

SHIGETO SHIMMURA^{a*†}, KOKI MATSUMOTO^{b†}, HIROMOTO YAGUCHI^a,
TOSHIYA OKUDA^b, SEIYA MIYAJIMA^b, AKIRA NEGI^b, JUN SHIMAZAKI^a
AND KAZUO TSUBOTA^a

^aDepartment of Ophthalmology, Tokyo Dental College, Chiba, Japan and ^bDepartment of Ophthalmology, Kumamoto University School of Medicine, Kumamoto, Japan

(Received Lund 14 September 1998 and accepted in revised form 25 March 1999)

Acidic electrolysed water (AEW) is a colorless solution prepared by the electrolysis of sodium chloride solution, which has potent anti-microbial activity against a wide variety of bacteria, fungi and virus. In this study, the safety and efficacy of an isotonic AEW solution (iAEW) was investigated both in vitro and in vivo using denuded corneas of guinea pigs. Povidone iodine (0.01–1.0%) was used as control. Exposure of *P. aeruginosa* to iAEW for 5 sec caused total inhibition of bacterial growth in vitro. Comparable results were obtained with 1% povidone iodine, while more dilute solutions required longer exposure times for similar effects. Cytotoxicity of iAEW on corneal epithelial cells in vitro was significantly less compared to 1% povidone iodine ($P < 0.05$), while minimal damage was observed in vivo by irrigation of the cornea with either iAEW or 1% povidone iodine. Treatment of *P. aeruginosa* with iAEW (15 sec) significantly inhibited the onset of corneal infection in guinea pigs. iAEW may offer an effective and safe method for disinfection of the ocular surface.

© 2000 Academic Press

Key words: Corneal ulcer; free radicals; disinfection; oxidative damage; Pseudomonas keratitis.

1. Introduction

Disinfecting agents used in clinical practice must effectively eliminate infectious organisms without being biohazardous or toxic to living tissue. Halide derivatives such as povidone iodine have been widely used for this purpose (Shelanski and Shelanski, 1956), however, problems such as hypersensitivity, coloration of skin and bacterial resistance cannot be ignored (Zamora, 1986). These agents are often diluted for the disinfection of the skin and ocular surface prior to intraocular surgery to avoid any toxicity to the corneal epithelium. Acidic electrolysed water (AEW) is an entirely new concept that has the potential of becoming an alternative to conventional disinfecting agents. AEW is a colorless, transparent solution prepared by the electrolysis of tap water containing sodium chloride (NaCl, 20% w/v), and is defined as having a pH of less than 3 and a reduction potential of greater than 1100 mV. Several devices are available on the market that produce AEW within these parameters, and are being used in the disinfection of medical instruments and food products as well as in the treatment of superficial infections such as gingivitis.

AEW alone has potent anti-bacterial, anti-fungal and anti-viral activities, which is speculated to be mediated by the actions of sodium hypochlorite

(NaOCl), the sodium salt of hypochlorous acid (Iwasawa and Nakamura, 1996). Hypochlorous acid is also produced physiologically by myeloperoxidase in polymorphonucleocytes (PMN) in the presence of Cl^- and I^- ions, and is involved in the bactericidal effects of PMNs. The anti-microbial mechanisms of povidone iodine are also not clear, although it is related with the presence of free iodine (I_2) in proximity to the bacterial cell surface (Zamora, 1986). In this respect, the bactericidal activities of povidone iodine and AEW may both depend on the availability of free halide molecules, iodine and chlorine, respectively.

One of the advantages of using AEW is that the production and degradation of AEW is minimally invasive to tissue, since the breakdown of AEW only produces saline (NaCl) and traces of chloride gas. This may offer an advantage over iodine products which have been reported to cause alterations in thyroid function as a result of increased iodide levels (Lyen et al., 1982). The present study was designed to evaluate the feasibility and safety of using AEW on the ocular surface as a possible means of disinfection prior to ocular surgery.

2. Materials and Methods

Bactericidal Effects of Isotonic AEW in vitro

AEW was prepared by the electrolysis of tap water containing sodium chloride (NaCl, 20%) (Acitron-S, MAC Japan, Tokyo, Japan) according to instructions provided by the manufacturer. Since the osmotic

* Address correspondences to: Shigeto Shimmura, Department of Ophthalmology, Tokyo Dental College, 5-11-13 Sugano, Ichikawa, Chiba 272-8513, Japan. E-mail: shige@eyebank.or.jp

† Both authors contributed equally to this work.

pressure of AEW thus produced is hypotonic, isotonicity was maintained by the addition of extra NaCl (4.0 g l^{-1}), which was confirmed by an osmometer. The addition of extra NaCl did not affect the pH (2.4) or redox potential (1100 mV) of the solution (iAEW). iAEW was prepared and stored at 4°C in opaque containers, and used within 1 week of preparation.

Pseudomonas aeruginosa (ATGC strain) were harvested in SCDLP medium (Soybean-Casein Digest Broth with Lecithin and Polysorbate 80, Nihon Seiyaku, Tokyo) at a concentration of $2.9 \times 10^5 \text{ CFU ml}^{-1}$ and mixed 1:1 with iAEW for reaction times of 5, 15, 30, 60, 180, 300 and 900 sec. Following the specified reaction time, $10 \mu\text{l}$ of the bacteria/iAEW solution was suspended in 1 ml of SCDLP medium and cultured for 48 hr at 35°C . Povidone iodine solutions (1.0, 0.1 and 0.01%) served as control. After the 48 hr incubation period, the bactericidal effects of each solution was determined by observing for any bacterial growth in culture. The experiment was repeated twice.

Prophylactic Effects of Isotonic iAEW in vivo

Albino Hartley guinea pigs of both sexes (400–450 g) were used and treated according to the ARVO Statement for the Use of Animals in Ophthalmology and Vision Research. The clinical strain of *P. aeruginosa* used in the in vivo study [serotype I, elastase (+), alkaline protease (+)] was isolated from a patient with a severe corneal ulcer (Matsumoto et al., 1998), and stored in 10% skimmed milk medium at -70°C until use. A 0.1 ml sample of medium was cultivated in 5 ml of tryptose broth (Eiken Chemical, Tokyo, Japan) with reciprocal shaking a 1 Hz at 32°C for 12 hr, and *P. aeruginosa* were subsequently collected by centrifugation at 3500 rpm for 20 min. One ml samples of the bacterial suspension ($8 \times 10^8 \text{ CFU ml}^{-1}$) were centrifuged at 9000 rpm for 3 min, and treated with 0.95 ml of either iAEW or saline control for 15 sec. Bacteria were then collected by centrifugation for 2 min, washed once and suspended in sterile saline. *P. aeruginosa* were therefore exposed to iAEW for a total of 135 sec prior to use in the animal experiment.

After guinea pigs were anesthetized topically with 0.4% oxybuprocaine hydrochloride and systemically with pentobarbital sodium (25 mg kg^{-1}), a 4.0 mm paper disc (Whatman International Ltd. Maidstone, U.K.) immersed in 1-heptanol (Nacalai Tesqu, Kyoto, Japan) was applied to the right cornea of the guinea pigs for 1 min. The paper discs were then removed, creating a reproducible circular defect in the corneal epithelium. Epithelial defects were made in all animals since *P. aeruginosa* cannot efficiently infect corneas with intact epithelium. After the corneal surface was washed with 40 ml of sterile saline, $30 \mu\text{l}$ of bacterial suspension treated with either isotonic iAEW or saline control ($n = 6$ each) was applied to the denuded area of each cornea. Signs of inflammation were observed

TABLE I
Criteria and scoring of corneal lesions after the inoculation of organisms

Macroscopic finding	Severity	Score
Epithelial damage	Irregular epithelium	1
	Epithelial erosion	2
	Mild ulcer	3
	Severe ulcer	4
Corneal opacity	Slightly opaque	1
	Iris visible	2
	Iris invisible	3
	Dense	4
Area (ratio of lesion to whole cornea)		Subscore
	1/10	0.1
	1/5	0.2
	2/5	0.4
	3/5	0.6
	4/5	0.8
	5/5	1.0

Corneal damage index (CDI). The grade of corneal damage was calculated as follows: $\text{CDI} = (\text{epithelial damage score} \times \text{area subscore}) + (\text{opacity score} \times \text{area subscore})$.

for 5 days, and then eyes were enucleated for histological evaluation after animals were killed with an overdose of sodium pentobarbital. Sections were fixed with 10% formalin, embedded in paraffin and stained with hematoxylin and eosin (HE).

The grade of corneal inflammation was semi-quantified by the corneal damage index (CDI) as described in our previous publication (Matsumoto et al., 1998), with some modifications as shown in Table I. The modifications were to allow better evaluation of the milder changes observed in this study, compared to the previous study that directly inoculated the stroma with *P. aeruginosa*. Statistical analysis was carried out using the ANOVA test.

Cytotoxic Effects of iAEW

The cytotoxicity of iAEW was observed in vitro using an immortalized human corneal epithelial cell line (T-HCEC) cultured in SHEM medium in 250 ml flasks (Iwaki Glass Inc., Tokyo) as previously described (Araki-Sasaki et al., 1995; Shimmura and Tsubota, 1997). Prior to experiments, cells were passaged to 96 well plates (Iwaki) at a seeding density of 10^4 cells per well and incubated for 48 hr until confluence. T-HCEC were then exposed to either isotonic iAEW, PBS(–) or povidone iodine saline solution (0.1, 0.1 or 1.0%) ($n = 8$) for a total of 15 sec. Each test solution was aspirated and replaced with fresh SHEM medium containing 0.4% trypan blue to stain devitalized cells. The number of non-viable cells in each group was expressed as the percentage of trypan blue positive cells per well. The experiment was repeated in triplicate and statistical

TABLE II
Bactericidal effects of iAEW against *P. aeruginosa* ATGC strain in vivo

Reaction time	5 sec	15 sec	30 sec	60 sec	3 min	5 min	15 min
iAEW	(-)	(-)	(-)	(-)	(-)	(-)	(-)
PI 1%	(-)	(-)	(-)	(-)	(-)	(-)	(-)
PI 0.1%	(+)	(+)	(+)	(+)	(+)	(-)	(-)
PI 0.01%	(+)	(+)	(+)	(+)	(+)	(+)	(+)

(+): Bacterial growth after 48 hr incubation at 35°C in SCDLP medium. (-): Complete inhibition of bacterial culture. iAEW: Isotonic acidic electrolysed water. PI: Povidone iodine.

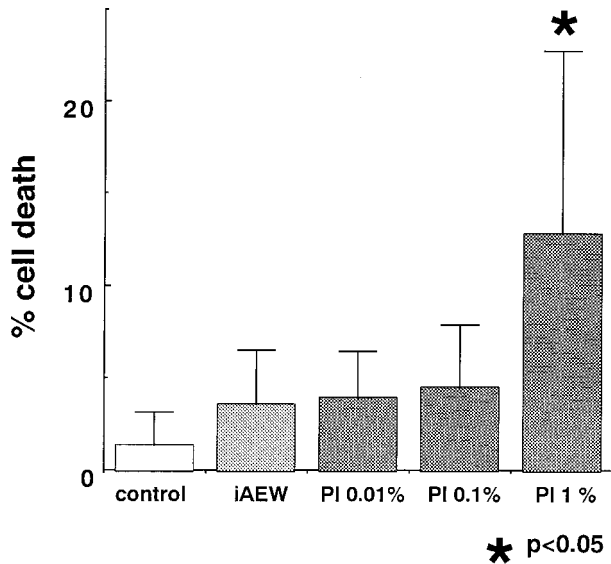


FIG. 1. Mean percentage of non-viable cells per well as determined by the trypan blue exclusion test. iAEW: Isotonic acidic electrolysed water, PI: povidone iodine. Mean \pm 1 s.d., $n = 8$ each, $*P < 0.05$ against all other groups. Statistical analysis was carried out by the one-way ANOVA test.

analysis was performed using the one-way ANOVA test.

Cytotoxicity of iAEW and povidone iodine in vivo was also examined by irrigating the ocular surface of Albino Hartley guinea pigs with either iAEW, 1% povidone iodine or saline control for 15 sec. Corneal

defects were not created in this experiment in order to simulate prophylactic disinfection prior to surgery. Clinical grading of inflammation was carried out using the CDI score as described above.

3. Results

Bactericidal Effects and Cytotoxicity

Preparation of AEW according to the manufacturer's protocol produces a hypotonic solution that may be detrimental to the mucosal tissue of the ocular surface. We have confirmed that modifying AEW to an isotonic solution still meets the standards for pH and reduction potential specified by the maker, and further sought to demonstrate the efficacy of isotonic iAEW in vitro and in vivo. Table II shows the bactericidal effect of iAEW compared to that of serially diluted povidone iodine solutions. Both iAEW and 1% povidone iodine completely inhibited *P. aeruginosa* growth within 5 sec of exposure. More dilute povidone iodine solutions required longer exposure times for comparable effects.

A cytotoxicity assay using a corneal epithelial cell line was performed in order to compare the effects of iAEW and serially diluted povidone iodine solutions. Figs 1 and 2 show the mean percentage of non-viable cells as determined by the trypan blue exclusion test, and a representative photograph respectively. Although iAEW and 1% povidone iodine were equally effective in bactericidal activity, the cytotoxicity assay

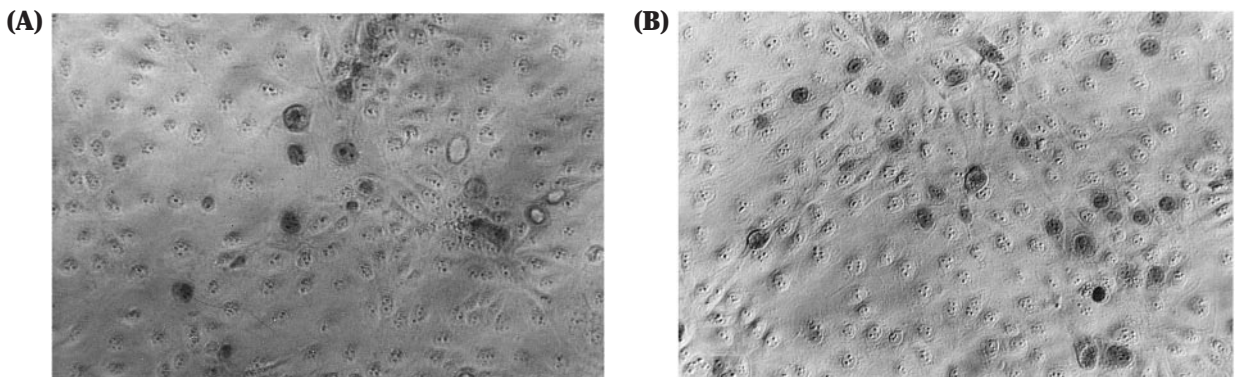


FIG. 2. Typical micrographs of trypan blue stained cultured corneal epithelial cells treated with either iAEW (A) or povidone iodine (B). The confluent sheet of cells were intact in both groups.

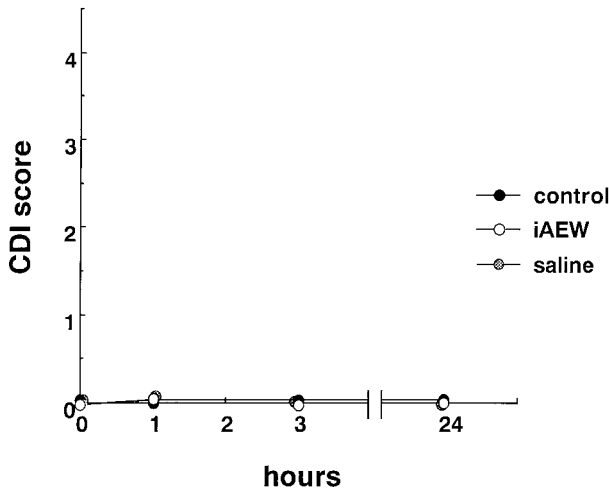


FIG. 3. The effects of iAEW, 1% povidone iodine or saline alone on corneas of untreated guinea pigs. Signs of inflammation were graded according to the CDI scale, which did not reveal any signs of inflammation for up to 48 hr.

showed significantly less damage in T-HCEC exposed to iAEW compared to cells treated with 1% povidone iodine. The cytotoxicity study performed in vivo showed very little change in CDI scores following irrigation of guinea pig corneas with iAEW, 1% povidone iodine or saline (Fig. 3). Although iAEW was less cytotoxic in vitro, this difference was not demonstrated on a macroscopic level in vivo.

Prophylactic Effects of iAEW in vivo

Denuding of the corneal epithelium in the guinea pigs was performed to mimic the compromised condition of the ocular surface following ocular surface and intraocular surgery. Bare stroma is an ideal substrate for the adhesion of microbes to initiate an infectious reaction that can lead to ulceration and perforation of the cornea. Fig. 4(A) is a representative macroscopic view of a guinea pig 2 days following inoculation with *P. aeruginosa* treated with control saline. Most corneas in the control group showed several abscess-like lesions in addition to corneal erosion and ground glass-like opacity up to day 5 [Fig. 4(B)]. Conjunctival injection and chemosis were more intense in the control group. Five out of six control corneas showed improvement following initial changes, however, one cornea developed a severe ulcer similar to those observed when *P. aeruginosa* is directly injected into stromal tissue (Matsumoto et al., 1998). Corneas in the iAEW group showed early reduction in erosion size, but presented with ground glass-like opacity of the lesion 2 days after inoculation [Fig. 4(C)]. Most of the opacity as well as the erosion itself healed by day 5 [Fig. 4(D)]. One cornea developed a mild abscess-like lesion that healed by the end of the study, leaving a slightly opaque lesion in the sub-epithelial area. CDI scores showed a statistically

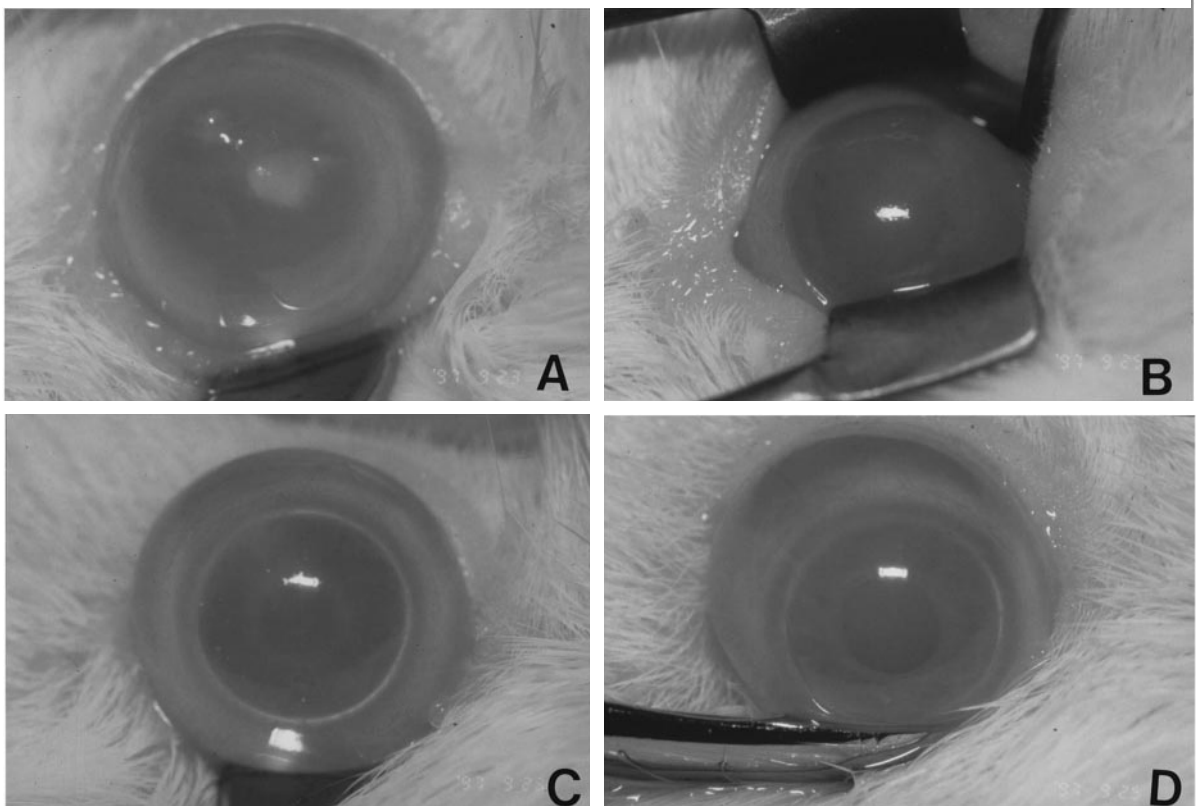


FIG. 4. Representative macroscopic view of corneas in control (saline-treated) and iAEW groups. Cornea in the control group (animal No. 2) on day 2 (A) and day 5 (B) showing abscess-like lesions in addition to corneal erosion and ground glass-like opacity. Representative cornea in the iAEW group (animal No. 5) on day 2 (C) with milder opacity than control that healed by day 5 (D).

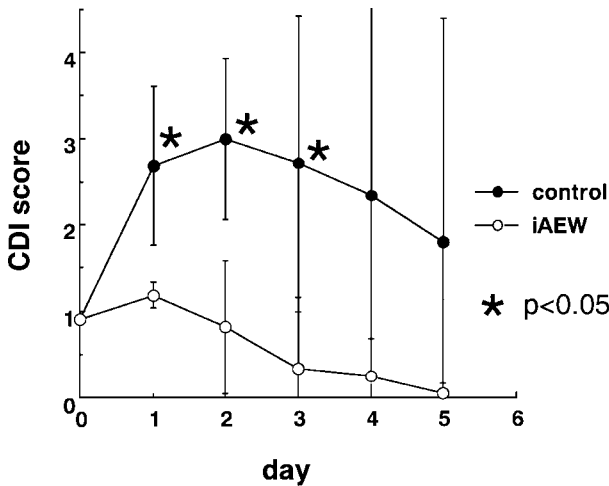


FIG. 5. CDI scores of corneas in the iAEW group and control during the 5 day study period. All corneas at the beginning of the study had CDI scores of 0.9, since scoring was performed after denuding of the epithelium. Mean \pm 1 s.d., $n = 6$ each, * $P < 0.05$, inter-group analysis was assessed by the ANOVA test.

significant difference at days 1, 2 and 3 (Fig. 5). All corneas at the beginning of the study had scores of 0.9 since evaluation was done following treatment with heptanol.

Histopathology of corneas of the iAEW group performed at the end of the study revealed normal corneal architecture with no appreciable swelling in 5 out of 6 eyes [Fig. 6(A)]. Mild corneal swelling

suggestive of endothelial damage was observed in only one eye. In contrast, most corneas in the control group showed varying degrees of corneal swelling and inflammatory cell infiltration [Fig. 6(B)]. Corneal architecture was damaged to various degrees, with the most severe cornea showing massive cellular infiltration in all layers of the stroma and loss of epithelium and endothelium as well as liquefactive necrosis [Fig. 6(C)].

4. Discussion

Bacterial infection of the ocular surface can cause a variety of clinical pictures ranging from mild conjunctivitis to a rapidly progressing, purulent ulcer that can lead to perforation of the globe and blindness. The initial trigger in most cases is a compromised ocular surface with decreased barrier functions due to trauma, surgery, contact lens used or other pathologies. Bacteria that have evaded the anti-microbial barriers of the ocular surface adhere to subepithelial tissue which then becomes the focus of bacterial keratitis. Bacterial organisms commonly detected in infections of the ocular surface include *P. aeruginosa*, *Streptococcus pneumoniae*, *Staphylococci* and *Moraxella lacunata*. The degree of corneal damage depends on the virulence of bacterial toxins and the host response centered around PMNs (Kernacki and Berk, 1995) that can cause non-specific damage to tissue due to the release of proteases (Henson and Johnston, 1987)

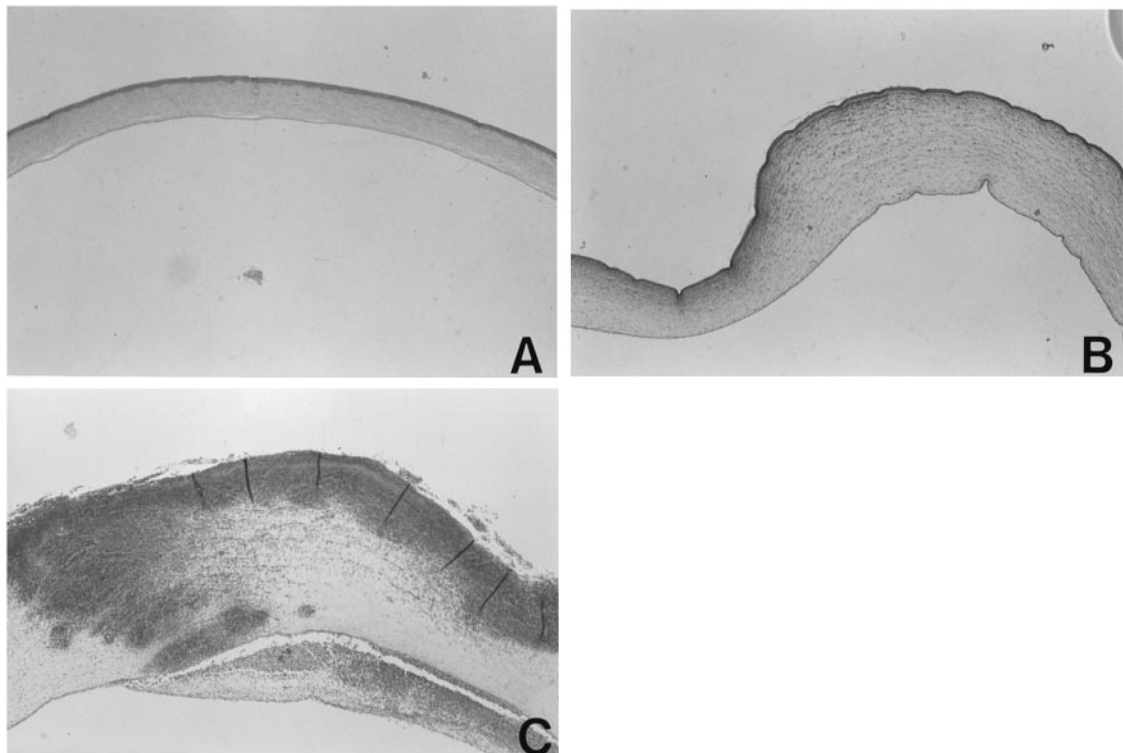


FIG. 6. (A) Hematoxylin eosin staining of the same animal as Fig. 2(D) of the iAEW group. (B) Histology of control cornea in Fig. 2(B) with prominent stromal edema and cellular infiltration. (C) Massive cellular infiltration in all layers of the stroma and loss of epithelium and endothelium as well as liquefactive necrosis in animal sustaining the greatest damage in the control group.

and reactive oxygen species (Cross et al., 1987; Malech, 1987). Although AEW has been reported to be effective against all species listed above as well as most other clinically relevant bacteria except for *Bacillus sp* (Iwasawa et al., 1993), *P. aeruginosa* was chosen as the pathogen in this study since this species is especially notorious for causing a rapid progression of ulcers that may lead to irreversible damage and loss of vision. Preparing an isotonic solution was an additional measure to decrease cytotoxicity to the ocular surface. Although the present study examined the bactericidal effects of iAEW on *P. aeruginosa* only, we have confirmed that the parameters for defining AEW activity (pH of 2.4 or less, a redox potential of approximately 1100 mV) were unchanged following isotonicity.

Prophylactic measures are taken prior to surgery as a means to eliminate pathogens from the surgical field and surgical staff, that may become a cause of infection in the unhealed wound. Various antiseptics are available in the market for the purpose of sterilizing tissue and surgical instruments. Povidone iodine is one of the most commonly used solutions that has proven its efficacy over the years of use since being introduced in the market. Although the safety of povidone iodine is also well established, high concentrations applied to mucous membranes are reported to cause a 5–10-fold greater increase in serum iodine levels when compared to cutaneous absorption (Zamora, 1986). This has caused some concern as to the effects on thyroid function, especially in children (Lyen et al., 1982). Although the quantity of povidone iodine used in ophthalmic surgery may not pose any problems systemically, it may contribute to corneal epithelial damage that may affect the field of view during intraocular surgery. The results of the trypan blue dye exclusion test (Fig. 1) shows that iAEW may be less cytotoxic in this regard.

One of the drawbacks of iAEW is that its bactericidal effects are rapidly lost when exposed to organic material, including living tissue. Although iAEW may temporarily eliminate microbes on the ocular surface, bactericidal effects may be less effective for microbes within the corneal stroma, Meibomian ducts and ciliary follicles. When iAEW was used in an experimental *P. aeruginosa* bacterial ulcer in guinea pigs as reported in our previous study (Matsumoto et al., 1998), there was no difference in prognosis compared to saline control (data not shown). This is probably due to the fact that iAEW lost its bactericidal properties before reaching pathogens in the deeper layers of the stroma.

Another potential application for AEW in the field of ophthalmology is the disinfection of contact lens.

Although the few commercially available devices for producing AEW are still costly and cumbersome, the household use of AEW may become possible pending improvements in design and technology. Since AEW is a colorless, non-irritating solution, it has the potential of becoming a major disinfecting agent of the skin and mucosal tissue including the ocular surface. Our study has shown that adjusting the osmolarity of AEW to physiological levels does not compromise its bactericidal activity against *P. aeruginosa*, which further improves the safety of using AEW in the ocular surface.

References

- Araki-Sasaki, K., Ohashi, Y., Sasabe, T., Hayashi, K., Watanabe, H., Tano, Y. and Handa, H. (1995). An SV 40-immortalized human corneal epithelial cell line and its characterization. *Invest. Ophthalmol. Vis. Sci.* **36**, 614–21.
- Cross, C. E., Halliwell, B. and Borish, E. T. (1987). Oxygen radicals and human disease. *Ann. Intern. Med.* **107**, 526–45.
- Henson, P. M. and Johnston, R. B. J. (1987). Tissue injury in inflammation: oxidants, proteinases, and cationic proteins. *J. Clin. Invest.* **79**, 669–74.
- Iwasawa, A. and Nakamura, Y. (1996). Bactericidal effect of acidic electrolyzed water-comparison of chemical acidic sodium hydrochloride (NaOCl) solution. *Kansenshogaku Zasshi.* **70**, 915–22.
- Iwasawa, A., Nakamura, Y. and Mizuno, T. (1993). Bactericidal activity of aqua oxidation water against clinically isolated strains. *Nihon Kankyou Kansen Gakkai-shi.* **8**, 11–6.
- Kernacki, K. A. and Berk, R. S. (1995). Characterization and arachidonic acid metabolism and the polymorphonuclear leukocyte response in mice infected intracorneally with *Pseudomonas aeruginosa*. *Invest. Ophthalmol. Vis. Sci.* **36**, 16–23.
- Lyen, K. R., Finegold, D., Orsoni, R., Herd, J. E. and Parks, J. S. (1982). Transient thyroid suppression associated with topically applied povidon-iodine. *Am. J. Dis. Child.* **136**, 369–370.
- Malech, H. L. (1987). Neutrophils in human diseases. *N. Engl. J. Med.* **317**, 687–94.
- Matsumoto, K., Shimmura, S., Goto, E., Saito, K., Takeuchi, T., Miyajima, S., Negi, A. and Tsubota, K. (1998). Lecithin-bound superoxide dismutase in the prevention of neutrophil-induced damage of corneal tissue. *Invest. Ophthalmol. Vis. Sci.* **39**, 30–35.
- Shelanski, H. A. and Shelanski, M. V. (1956). PVP-iodine: history, toxicity, and therapeutic uses. *J. Int. Coll. Surg.* **25**, 727–734.
- Shimmura, S. and Tsubota, K. (1997). Ultraviolet B-induced mitochondrial dysfunction is associated with decreased cell detachment of corneal epithelial cells in vitro. *Invest. Ophthalmol. Vis. Sci.* **38**, 620–6.
- Zamora, J. L. (1986). Chemical and microbiologic characteristics and toxicity of povidone iodine solutions. *Am. J. Surg.* **151**, 400–406.